



## Case Report

# A case report on the management of mandibular midline diastema by using laser as a treatment modality

Pooja Bharadwaj<sup>1\*</sup>, Roopali Patel<sup>2</sup>

<sup>1</sup>Dept. of Periodontology, Rishiraj College of Dental Sciences and Research Centre, Bhopal, Madhya Pradesh, India

<sup>2</sup>Dept. of Oral Medicine and Radiology, Peoples College of Dental Sciences and Research Centre, Bhopal, Madhya Pradesh, India



### ARTICLE INFO

#### Article history:

Received 22-08-2024

Accepted 11-09-2024

Available online 20-09-2024

#### Keywords:

Central incisor  
Gingival embrasure  
Black triangle  
Aesthetics  
Reduction  
Frenectomy  
Laser

### ABSTRACT

A frenum is a fold of mucous membrane that connects the labial mucosa (lips) to the gingiva or that connects the tongue to the floor of the mouth and hence providing support to the lips and the tongue. The normal frenal attachment is at the level of mucogingival junction (mucosal) and hence maintaining a balance between the interproximal contacts of the anterior teeth of either maxilla or mandible. But if this frenal attachment is high or in other words if there is an aberrant frenum, then this type of frenal attachment either results in spacing between the anterior teeth or in some cases can lead to the loss of gingival embrasure resulting in the creation of black triangle between the anterior teeth. Present case report is on a 38 years old female whose chief complaint was spacing between the mandibular central incisors and upon intraoral examination, it was noted that there was an aberrant frenum which has also resulted in loss of gingival embrasure between the mandibular anterior teeth and hence this aberrant frenum was treated by a process called frenectomy by using a thermal treatment modality called as Laser. Upon follow up after 1 week, there was a reduction in spacing between mandibular central incisors.

This is an Open Access (OA) journal, and articles are distributed under the terms of the [Creative Commons Attribution-NonCommercial-ShareAlike 4.0 License](https://creativecommons.org/licenses/by-nc-sa/4.0/), which allows others to remix, tweak, and build upon the work non-commercially, as long as appropriate credit is given and the new creations are licensed under the identical terms.

For reprints contact: [reprint@ipinnovative.com](mailto:reprint@ipinnovative.com)

## 1. Introduction

Periodontology is a specialized branch of dentistry that deals with the structures that surrounds the teeth and the structures that provide support to the teeth. The surrounding structures involves the gingiva which is protecting the supporting structures of the teeth and the supporting structures of the teeth include periodontal ligament, cementum, and alveolar bone.<sup>1</sup> The entire integrity of the oral cavity is because of the presence of balance between the hard and the soft tissues of the teeth as any imbalance between these two components leads to significant problems like the disturbance in aesthetics, difficulty in speech and mastication.<sup>2</sup> One of the aesthetically concerned soft tissue

of the oral cavity is the frenum. Frenum refers to the soft tissue fold of connective tissue, which connects the lips or the labial mucosa with the gingiva as in case of maxilla and the labial surface of mandible; or connecting the tongue to the floor of mouth as in case of mandible where the frenum is present lingually too.<sup>3</sup> Usually there are four types of frenal attachment present in the oral cavity and they are as follows:<sup>4</sup>

1. Mucosal: Frenum attachment is at the level of mucogingival junction
2. Gingival: Frenum attachment is at the level of attached gingiva
3. Papillary: Frenum is attached to the tip of the papilla
4. Papilla penetrating: Frenum attachment extends from the tip of the papilla to the palatine process of maxilla.

\* Corresponding author.

E-mail address: [bharadwajpooja628@gmail.com](mailto:bharadwajpooja628@gmail.com) (P. Bharadwaj).

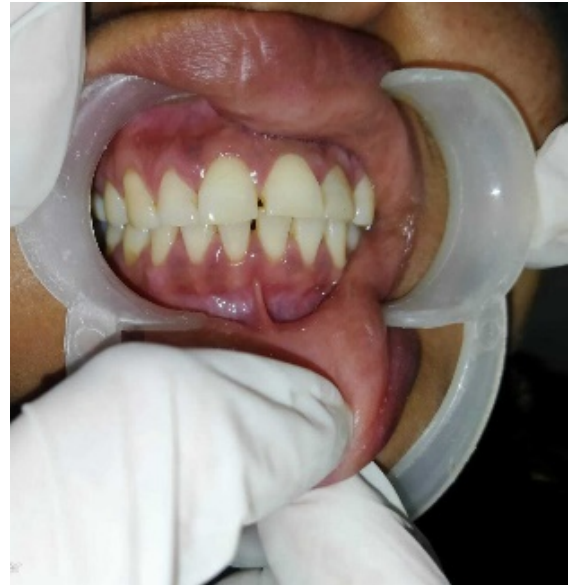Among these four frenal attachments present, the normal frenal attachment are the mucosal and gingival and the frenal attachment which are considered as high or as aberrant are papillary and papilla penetrating. But in my present case report the frenal attachment which was seen as aberrant was gingival type of frenal attachment as the tension test was positive for this type of frenal attachment.<sup>4</sup> This aberrant frenal attachment when present, can lead to the pulling away of the gingival margin which can lead to recession, or can prevent the space closure between the central incisors, leading to the creation of the midline diastema or sometimes loss of gingival embrasure between the central incisors which will further leads to the consequences such as hypersensitivity, root surface caries ( as because of recession) and compromise in the aesthetics ( as because of the creation of spacing between the anterior teeth, which results in an abnormality called as black triangle).<sup>5</sup> Henceforth to prevent or correct these consequences, the excision or relocation of this aberrant frenum is a necessity which is done by a procedure called as frenectomy (excision of frenal attachment) or frenotomy (relocation of high frenum) and this frenectomy can be done by two types of treatment modalities which are as follows.<sup>6</sup>

1. Conventional: Done by using scalpel and the procedure for which it is mainly indicated is frenectomy and not frenotomy
2. Thermal: Done by using lasers, electrosurgery, electrocautery and by this treatment modality both the frenectomy and frenotomy can be done.

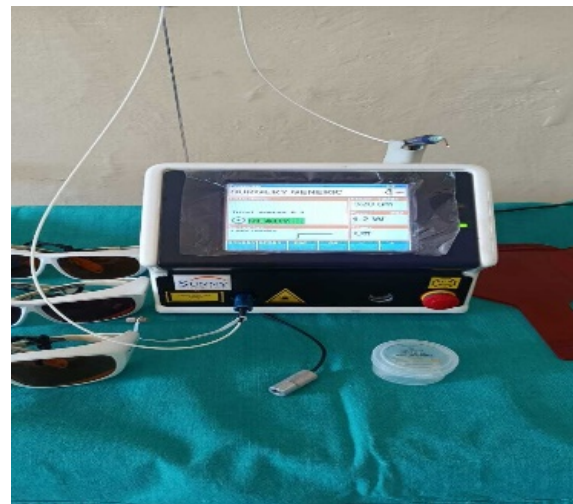## 2. Case Presentation

A 38 years old female patient reported to the department of Periodontology at Rishiraj College of Dental Sciences, with the chief complaint of spacing between the mandibular central incisors. The patient medical history and dental history were non-significant. In the extraoral examination, no abnormality was detected. Upon intraoral examination, that gingival type of frenal attachment was noted in between mandibular central incisors which has resulted in the creation of black triangle and diastema. So, a tension test was done which was positive and hence it was confirmed that this aberrant frenum had resulted in creation of mandibular midline diastema . The cause for her problem was explained to the patient and it was decided to excise this frenum by frenectomy and by using a Laser; a thermal modality. A week before the surgery, blood investigations were done to rule out any bleeding disorder that can result in bleeding during the surgery and after the surgery. The blood investigations were in normal range. On the day of surgery, the procedure was started with giving local infiltration near to the tip of the frenum but not directly into the frenum, as it will distort the frenum. Diode soft tissue laser was used with a 100-micron fibre tip and the frenum was excised

with the power setting of 1.5 Watt. Following the excision, the area was covered by the Periodontal pack to avoid any infection of the operated site followed by the prescription of analgesics and anti-inflammatory medications to reduce pain and swelling. I

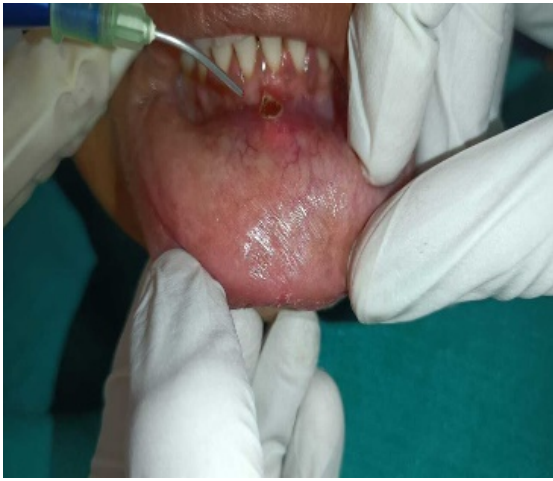

**Figure 1:** Pre-operative view showing gingival type of Aberrant frenal attachment between mandibular central incisors

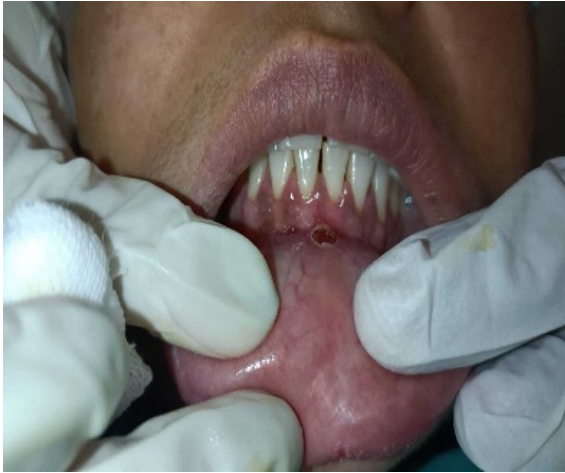

**Figure 2:** Thermal modality diode laser which is used in frenectomy.

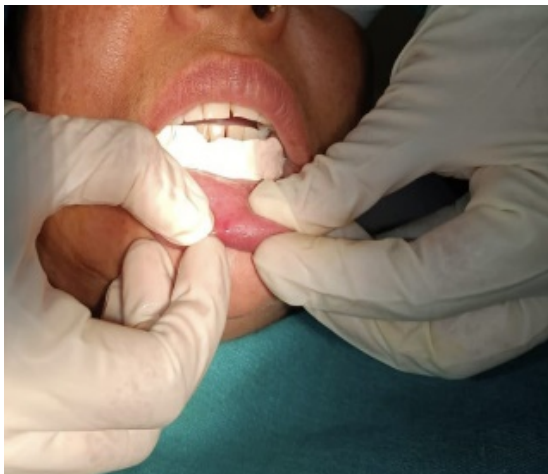
After one week the patient came for the follow up and it was noted that there was a reduction in the black triangle size as well as the spacing between the mandibular central incisors and no further complaint was recorded by the patient except the slight feeling of pain from the operated site for which the patient were further prescribed topical



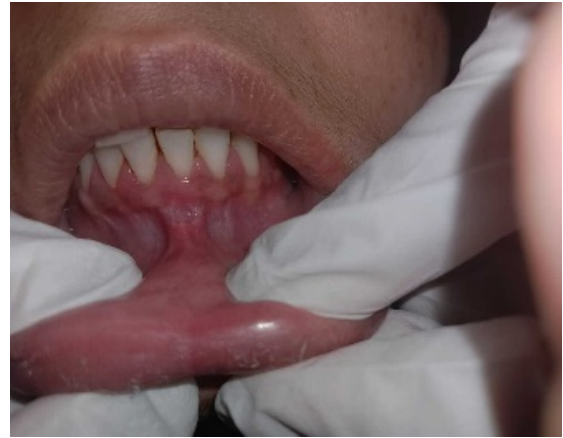**Figure 3:** Intraoperative view of excised frenal attachment



**Figure 4:** Immediate post-operative view of excised frenal attachment



**Figure 5:** Placement of periodontal pack over the excised frenum



**Figure 6:** Post 1 week follow up with the reduction in mandibular midline diastema

medication ad vitamin C tablets to aid in healing.

### 3. Discussion

In the present case report, it was shown that irrespective of any type of frenal attachment, it cannot be completely said right on a path that the frenal attachment which is not classified as high or aberrant cannot cause spacing between the central incisors or opening up of gingival embrasure /creation of black triangle between central incisors and hence the only way to clear this doubt is by carefully observing the frenum and to perform the tension test which in itself is self-satisfactory to rule out the cause of such conditions.<sup>7</sup> In our present case report, we have noticed the gingival frenal attachment as an aberrant frenal attachment which has resulted in the opening of gingival embrasure and the creation of spacing between the mandibular central incisors. Shobhna et al.<sup>8</sup> in a recent review of frenal attachments have shown that there are different types of aberrant frenal attachments which can be treated by various techniques like classical frenectomy, Z plasty, V-Y plasty, Millers technique, Laser, and electrocautery which correlates with the use of our treatment modality of Lasers in our case report. Nishita et al.<sup>9</sup> used Millers technique combined with the lateral pedicle flap so as to overcome the drawback of classical frenectomy technique of unaesthetic scarring of the tissue and the loss of interdental papillae, which correlates with our case report as in our case, we too have avoided the conventional treatment modality and had used Laser which did not create any scarring of the tissue. Shakir et al.<sup>10</sup> in their case had used V-Y plasty as a frenectomy technique which has resulted in a good aesthetic and functional outcome and they also mentioned the advantage of using Lasers as a treatment modality in comparison to the conventional treatment modality of scalpel which coincides with our case report in which good aesthetic and functional outcome

is achieved. Mahdi et al.<sup>11</sup> had described a modification of the conventional frenectomy technique using a sulcular incision on the palatal surface because of which the position of the frenum was changed apically without invading the papilla which upon healing had created a minimal surgical scar on the buccal surface with preserving the papilla and yielded optimal aesthetic results. In our case report, we have chosen laser as a treatment modality because of the small size and the superficial location of frenum which makes in complete sense, that Laser is made for such deliberate handling of small sized and superficially attached tissues.<sup>12</sup> The greatest advantage of Laser is that there is no bleeding intraoperatively, the procedure done by the laser is less time consuming as compared to the scalpel, there is no or less intraoperative pain at the time of surgery, and less chances of infection as the tip of the laser has the sterilization property.<sup>13</sup> In this case report, it was noted, that the patient experiences no pain, no bleeding at the time of surgery and the entire procedure was completed in just 15 minutes. However, one of the biggest disadvantages while using laser as a treatment modality is that healing is delayed because of the narrow zone of tissue denaturation at the margins, coagulation of some connective tissue elements and the temporary delaying of inflammation, production of collagen and phagocytic activity.<sup>14</sup> In this case report, the healing of the laser operated area was delayed which was reflected in the complaint of slight pain at the operated site after 1 week when the patient came for follow up. Another disadvantage of Laser is that since, laser is a type of thermal modality hence there are more chances of postoperative complications like swelling for which there is a need to prescribe serrati peptidase combination to the patient and in this case report serrati peptidase too were prescribed to the patient. However, despite of this disadvantages of laser, the frenectomy by laser is the preferred treatment modality by most of the patients as it has reduced surgical time, good haemostatic control, minimal or no pain and is highly suitable for those patients who had a fear of undergoing surgical intervention.<sup>15</sup>

#### 4. Conclusion

Identifying the high or aberrant frenum is a crucial diagnostic skill, as most of the times it is discovered as an accidental finding. The clinician must be able to rule out the cause of spacing between the central incisors and must not forget, that a high or aberrant frenum can also be the cause of diastema or opening of gingival embrasure between the central incisors. The clinician must also be aware of the consequences a high or aberrant frenum can cause and must be able to make aware the patient too about the consequences. The excision of the frenum is a case sensitive procedure and the clinician must have the knowledge too about what kind of modality is best suited

for each frenectomy procedure and what are the advantages and disadvantages of each modality. And which treatment modality can be best benefited to the patient. However, this modern era reclines towards lasers as it has lots of advantages over conventional procedures such as no sutures required, minimal anaesthesia but in reclining towards the modern era of Lasers, the clinician must not forget about the conventional modality of scalpel as we can only accept the modern modalities if we have the idea of the conventional modalities as it is an old saying that if the new ones are diamond, then the old ones are gold too.

#### 5. Source of Funding

None.

#### 6. Conflict of Interest

None.

#### References

1. Newmann M, Takei H, Klokkevold P, Carranza F. Anatomy of Periodontium. In: and others, editor. Carranza's Clinical Periodontology. vol. 2. Elsevier; 2011. p. 12–26.
2. Sheiham A. Oral health, general health and quality of life. *Sci Elic Public Health*. 2005;83(9):644.
3. Addy M, Dummer PM, Hunter ML, Kingdon A, Shaw WC. Study of the association of frenal attachment, lip coverage and vestibular depth with plaque and gingivitis. *J Periodontol*. 1987;58(11):752–7.
4. Priyanka R, Sruthi R, Ramakrishnan T, Emmadi P, Ambalavanan N. An overview of frenal attachments. *J Indian Soc Periodontol*. 2013;17(1):12–5.
5. Jhaveri H. Dr. PD Miller the father of periodontal plastic surgery. In: The Aberrant Frenum; 2006. p. 29–34.
6. Coletton SH. The mucogingival surgical procedures which were employed in re-establishing the integrity of the gingival unit. The frenectomy and the free mucosal graft. *Quintessence Int Dent Di*. 1977;8(7):53–61.
7. Placek M, Miroslavs, Mrklas L. Significance of the labial frenal attachment in Periodontal disease. Part 1; Classification and epidemiology of the labial frenum attachment. *J Periodontol*. 1974;45(12):891–4.
8. Bamel N, Mehta S, Vats N, Thind S, Jindal S. An overview of frenectomy: A review. *Int J Med Health Res*. 2021;7(4):13–5.
9. Bhosale N, Khadtare Y. Frenectomy by millers technique: A case report. *IP int J Periodontol Implantol*. 2020;5(4):177–80.
10. Shakir H, Panwar N, Nisanth N. Frenectomy: A Case Report. *EPRA Int J Res Dev*. 2020;6(2):138–41.
11. Kadkhodazadeh M. A modified frenectomy technique: a new surgical approach. *Gen Den*. 2018;66(1):34–8.
12. Devishree, Gujjari SK, Shubhashini PV. Frenectomy: a review with the reports of surgical techniques. *J Clin Diagn Res*. 2012;6(9):1587–92.
13. Singh VP, Uppoor AS, Nayak DG, Shah D. Black triangle dilemma and its management in esthetic dentistry. *Dent Res J*. 2013;10(3):296–301.
14. Aldelaimi TN, Mahmood AS. Laser-assisted frenectomy using 980 nm diode laser. *J Dent Oral Disord Ther*. 2014;2(4):1–6.
15. Akpınar A, Tokar H, Lektetur Alpan A. Postoperative discomfort after diode laser and conventional frenectomy. *Aust Dent J*. 2016;61(1):71–5.

**Author biography**

**Pooja Bharadwaj**, Senior Resident  <https://orcid.org/0000-0003-1138-5420>

**Roopali Patel**, Assistant Professor  <https://orcid.org/0009-0000-0380-9778>

**Cite this article:** Bharadwaj P, Patel R. A case report on the management of mandibular midline diastema by using laser as a treatment modality. *J Dent Spec* 2024;12(2):146-150.